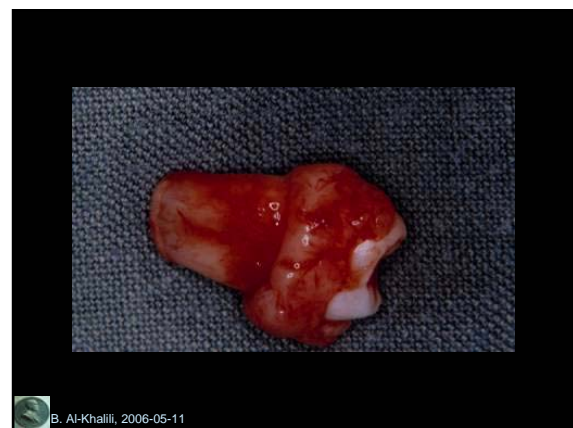
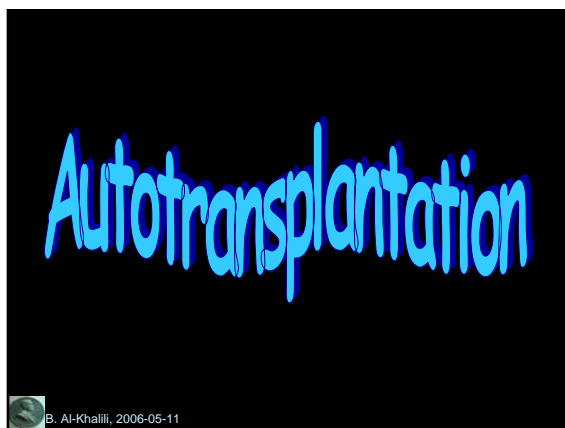
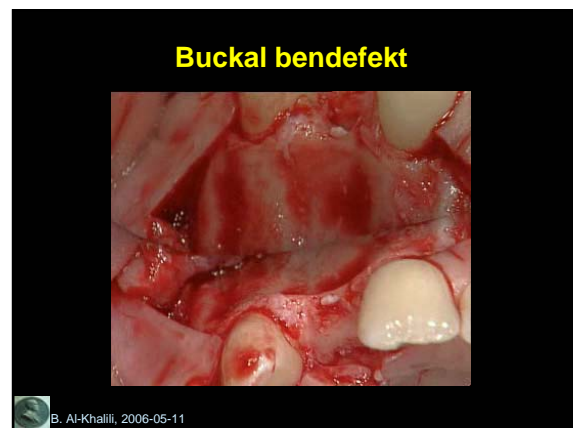
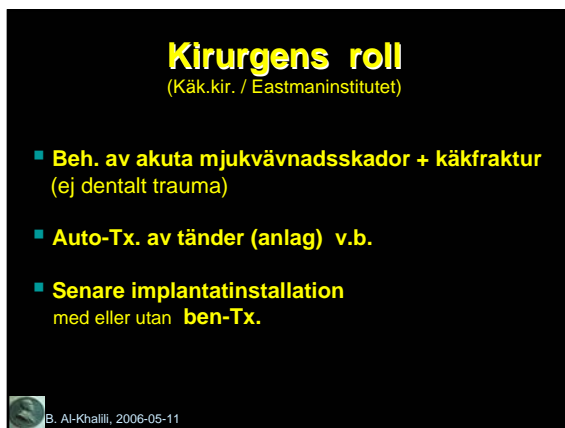
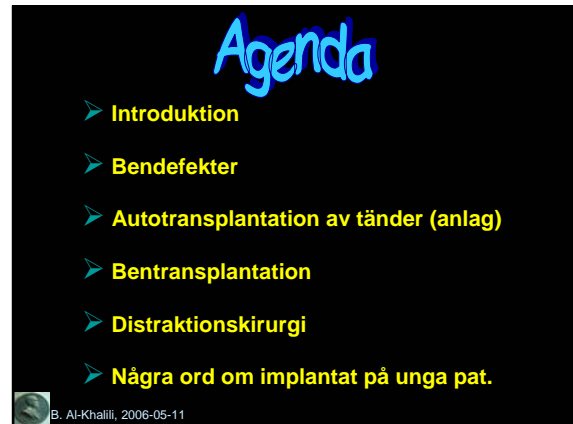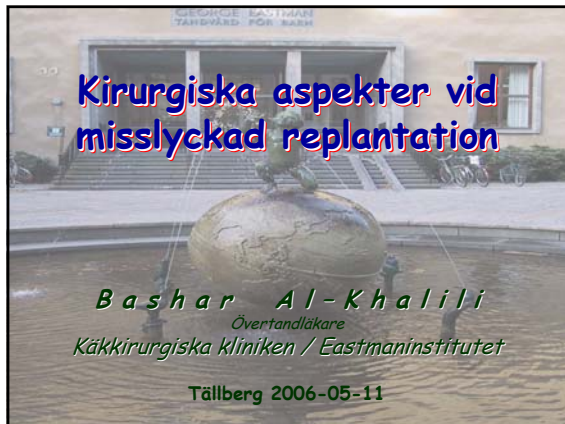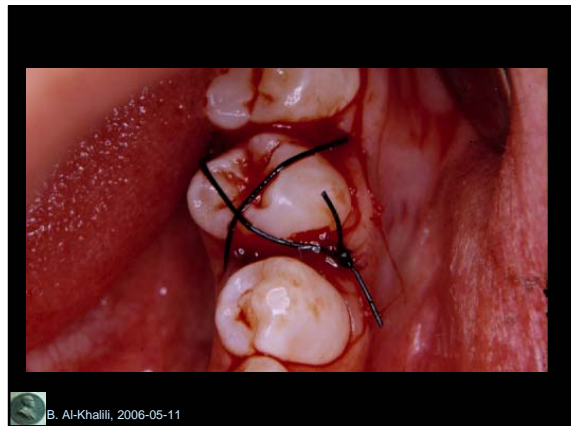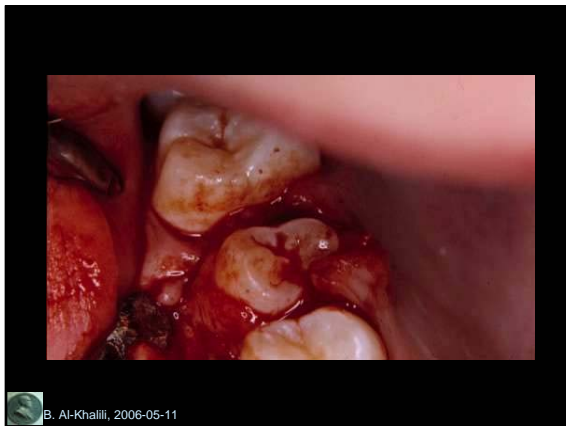Pat.fall

8-årig pojke
Replantation på ATV
Spruträdd
Fullt frisk
Inga symptom
11 rotbeh. hos ped.spec.
Svår trångställning

2002-11 8 år

B. Al-Khalili, 2006-05-11

2003-12 9 år

B. Al-Khalili, 2006-05-11

Beslut att extrahera 11 & 12 och genomföra auto-Tx. Av 45

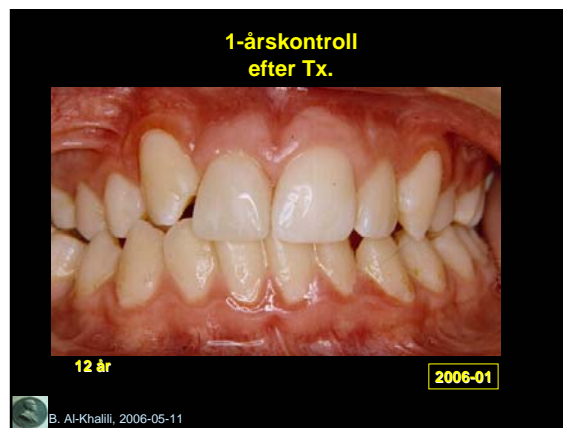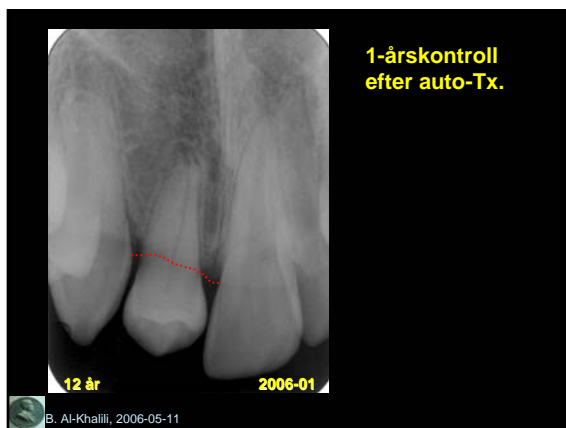
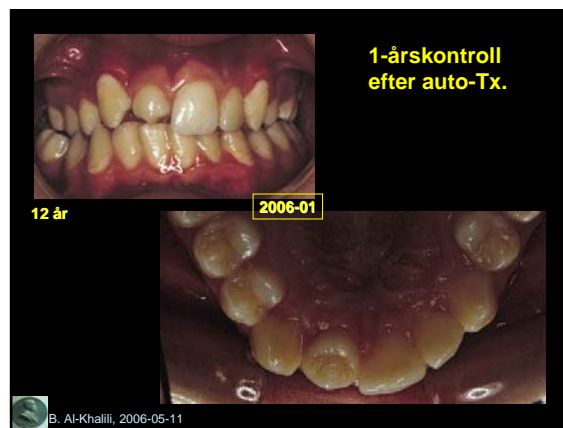
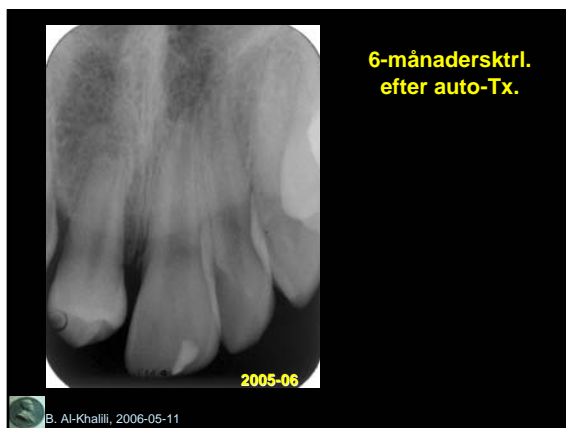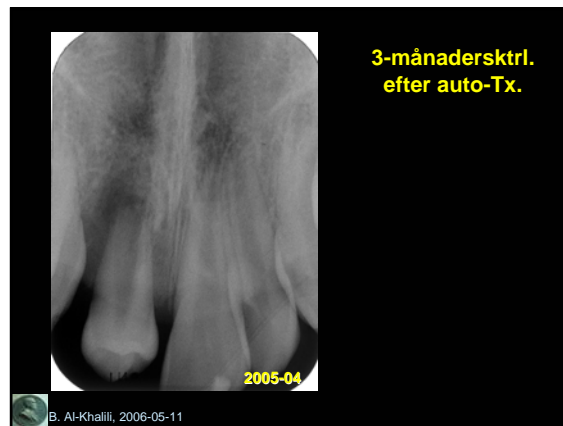
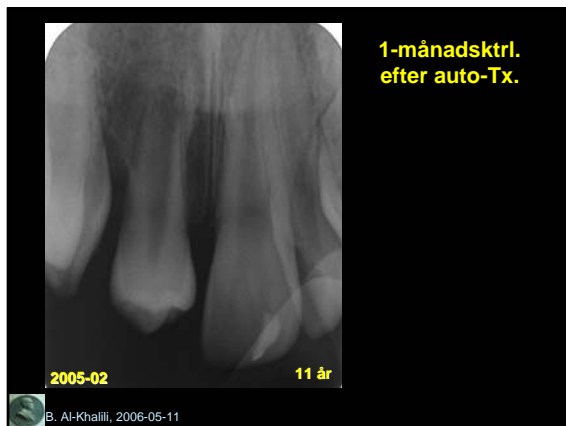
2003-12 9 år

B. Al-Khalili, 2006-05-11

Rtg.ktrl. efter auto-Tx.

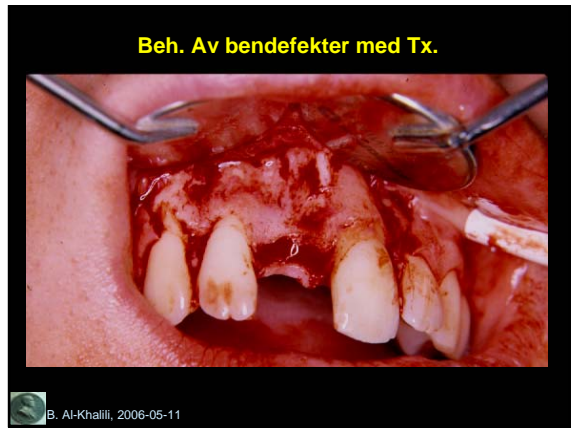
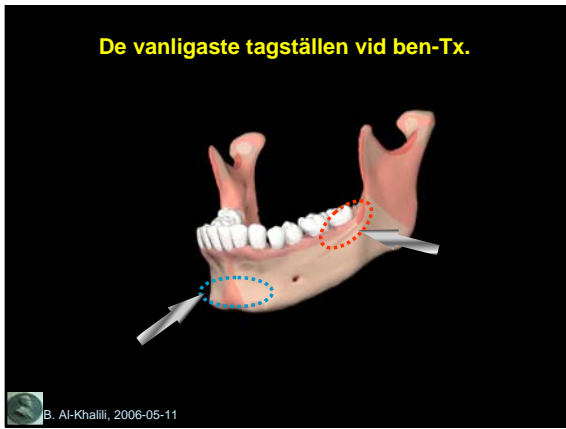
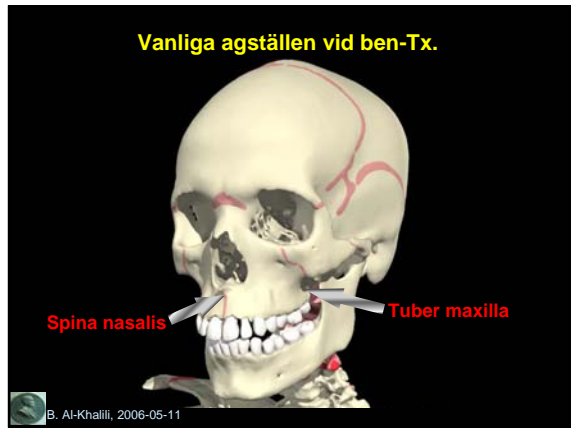
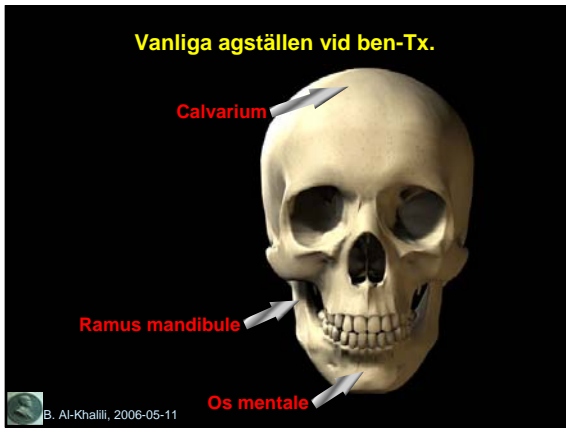
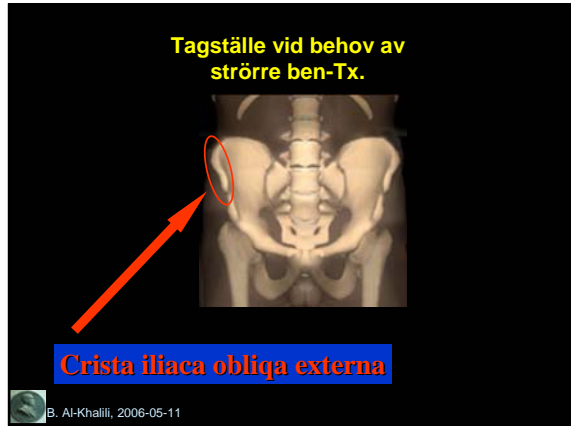
11 år 11 2005-01

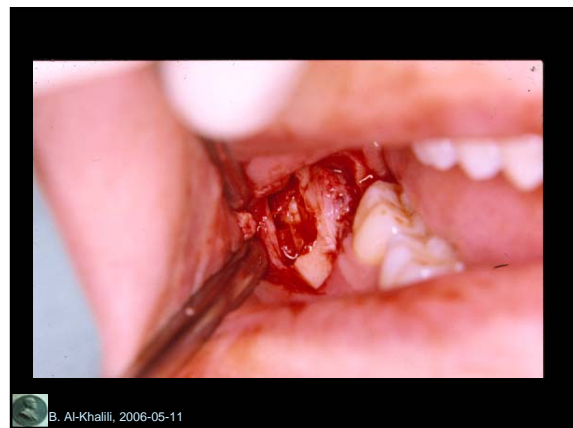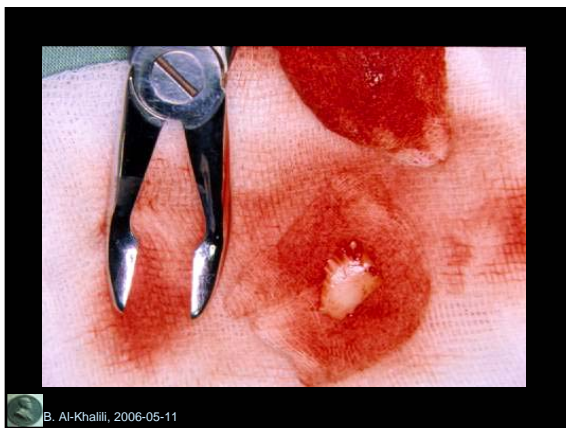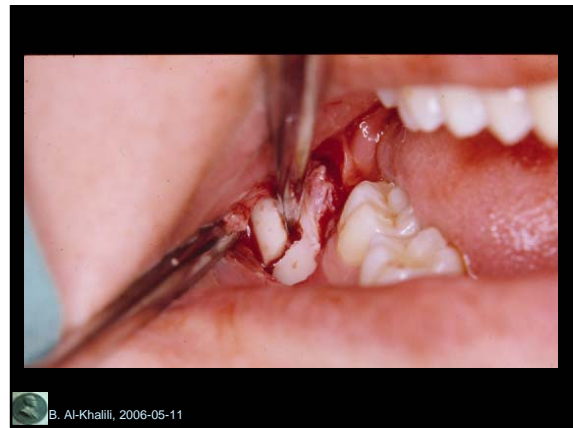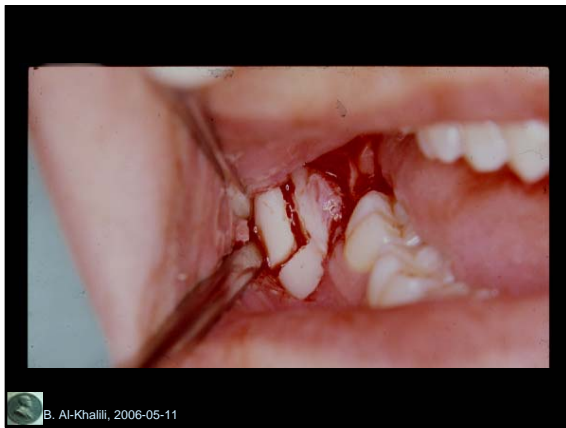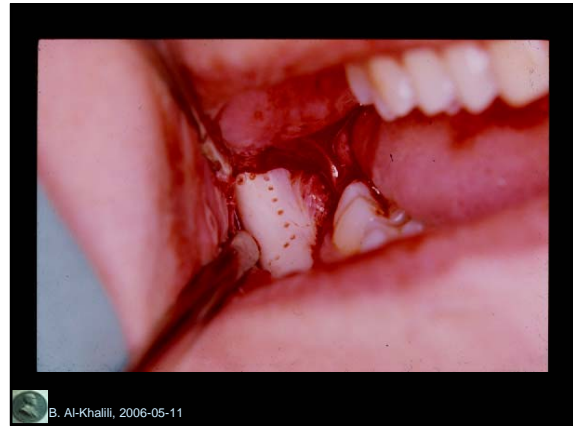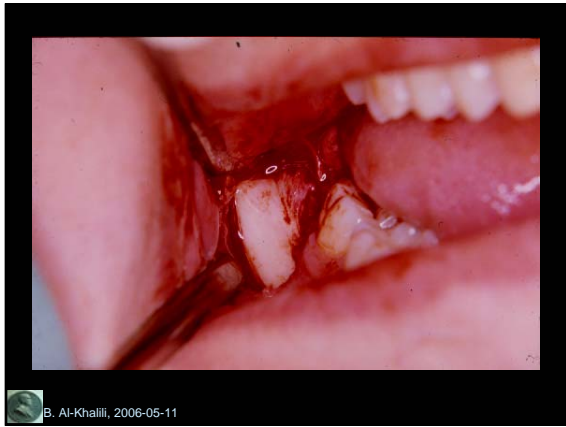B. Al-Khalili, 2006-05-11

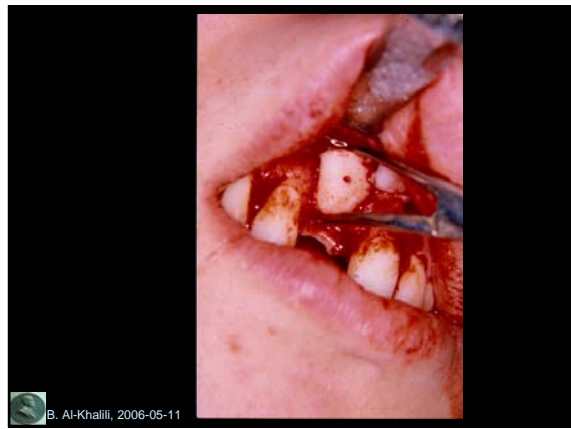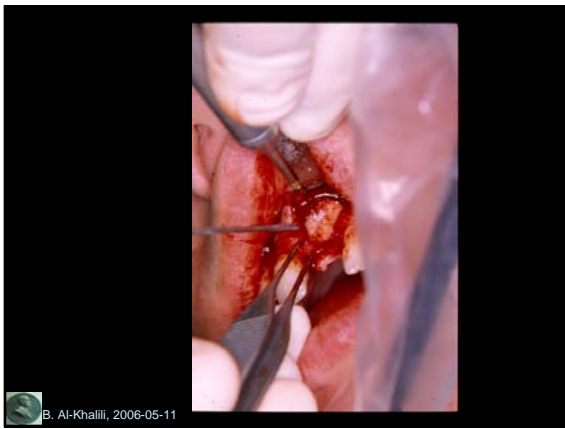
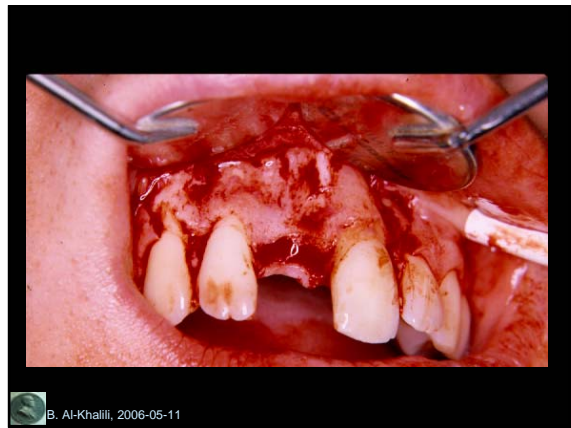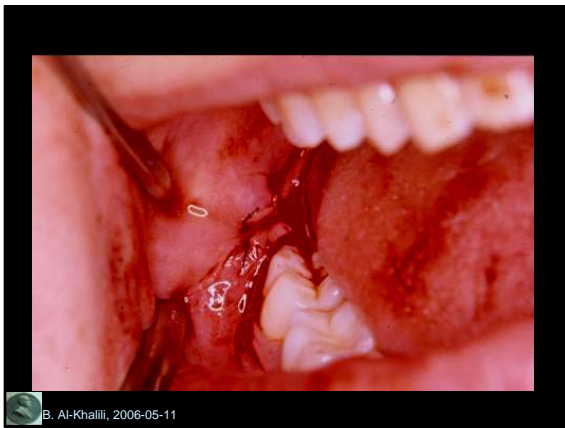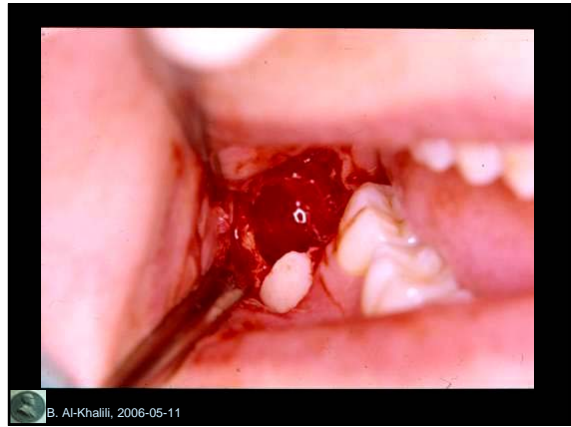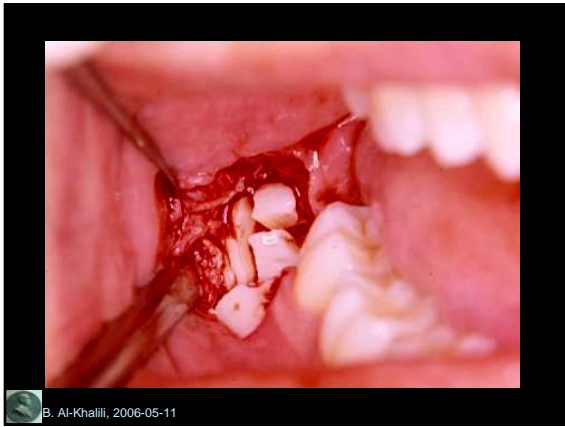


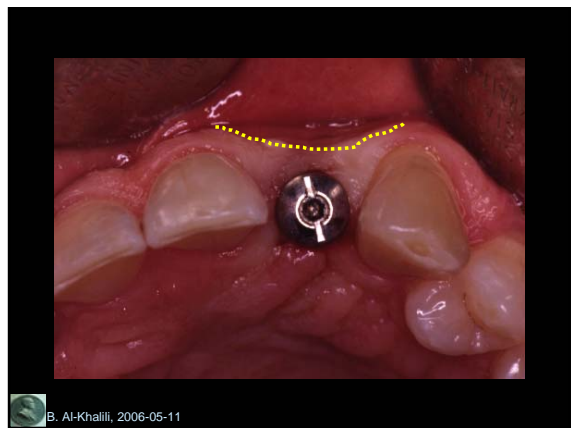
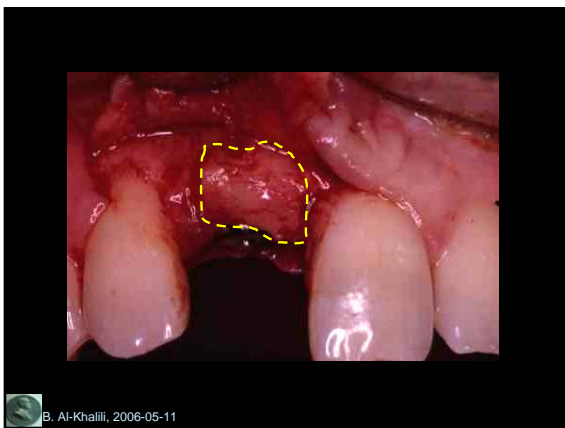
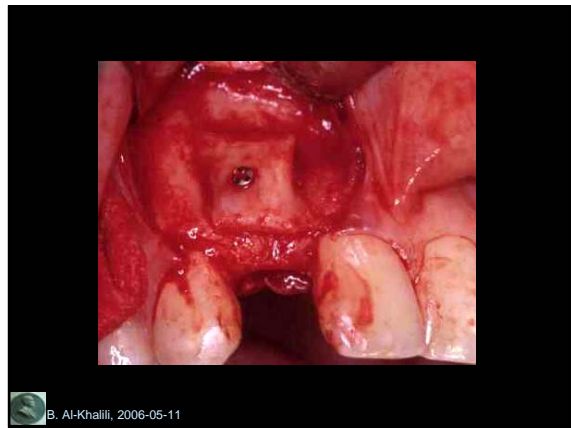
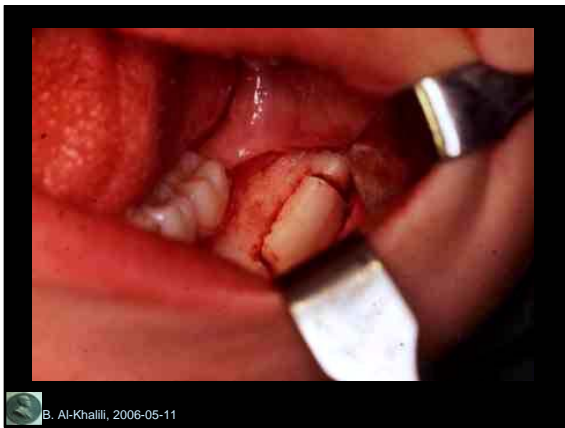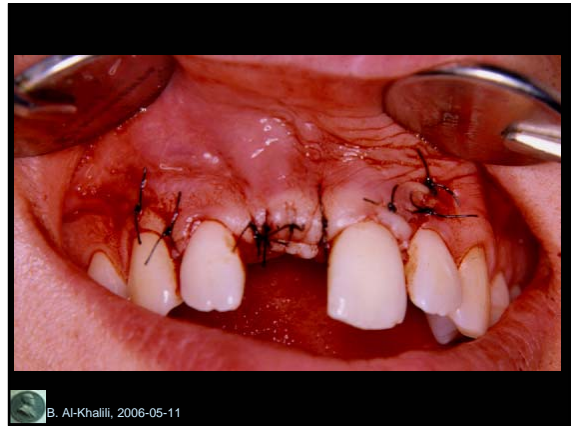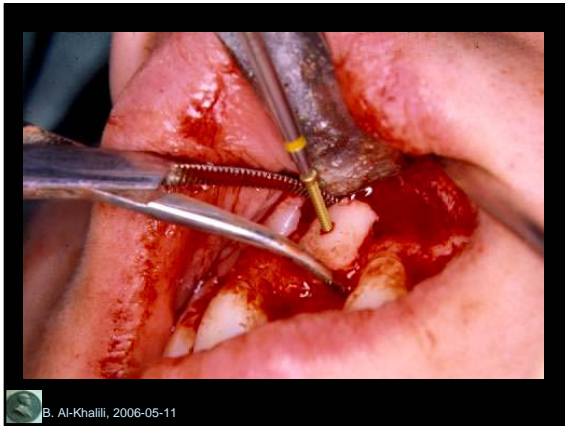Bentransplantation

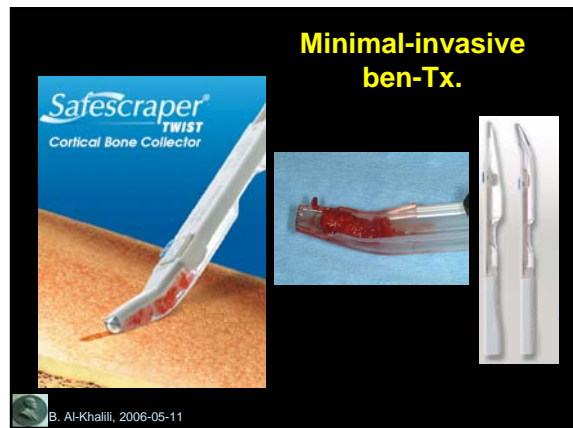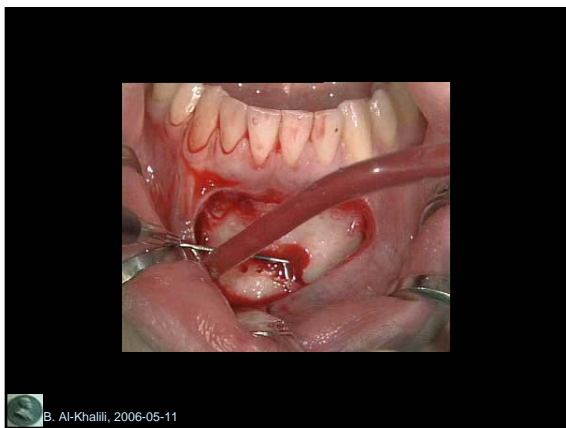
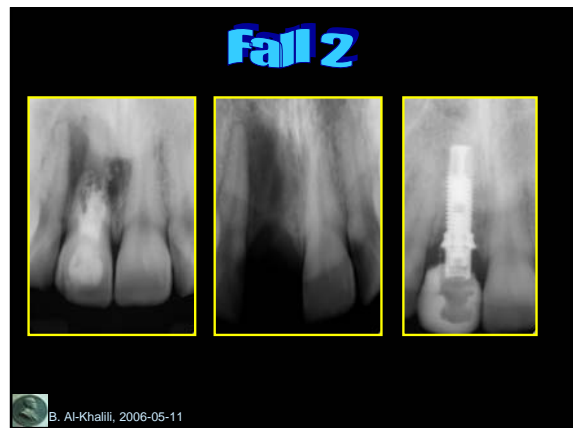
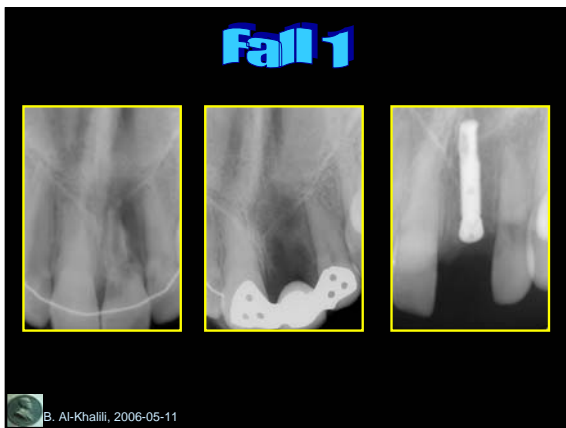
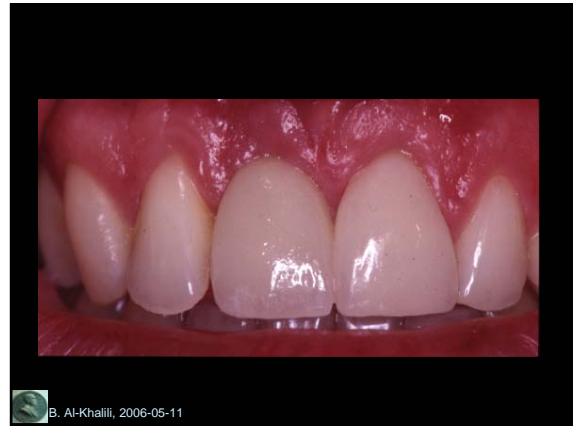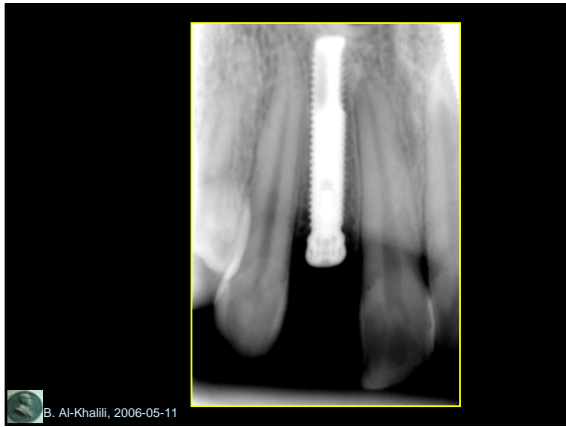
B. Al-Khalili, 2006-05-11





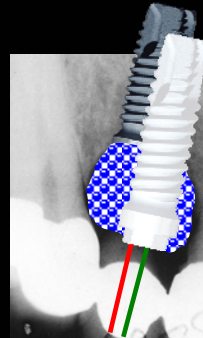






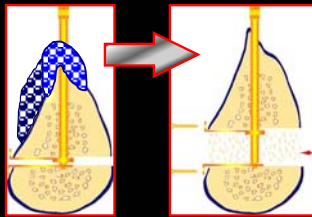
Bendistraktion

B. Al-Khalili, 2006-05-11



Vertikal
bendefekt

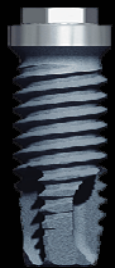Ortopedisk kirurgi 1900
Koncept utvecklades 1960-talet
av **Gavriel Ilizarov**, rysk ortoped



B. Al-Khalili, 2006-05-11



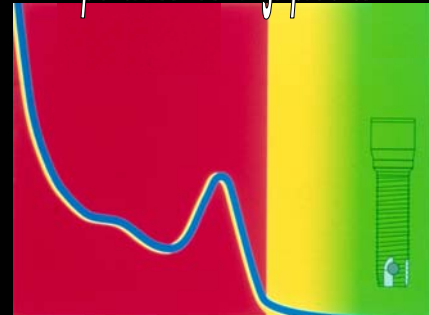
B. Al-Khalili, 2006-05-11



Några ord om
implantat
på
barn / ungdomar

B. Al-Khalili, 2006-05-11

Implantat och den unga patienten



B. Al-Khalili, 2006-05-11

Bashar.Al-Khalili@ftv.sll.se
Kristina.Stenback@ftv.sll.se
Margareta.Lundberg@ftv.sll.se

